



Cerebral Coenurosis in a Cat



John Ragsdale, DVM, PhD, DACVP and Norbert Takács, DVM, DACVP
New Mexico State University and New Mexico Department of Agriculture Veterinary Diagnostic Services
Poster P-3

HISTORY:

A two-years-old, spayed female, Domestic Short Hair cat (*Felis catus*) was presented with vestibular signs two months prior to euthanasia. The cat seemed to improve slightly with antibiotic therapy, but the neurologic symptoms progressively worsened. The neurologic signs progressed to anisocoria and an inability to ambulate. The owner and a veterinarian were bitten by the cat. A veterinary neurologist suspected the cat had lymphoma or feline infectious peritonitis. The cat was euthanized due to the deteriorating condition and the poor prognosis.

GROSS PATHOLOGY FINDINGS:

The cat was in good body condition. There was minimal postmortem decomposition of the carcass. The brainstem ventral to the cerebellum in the area of the pons contained a large compressible soft mass that distorted the architecture of the brainstem. On cross section of the brainstem, the mass was a 12 cm diameter cyst filled with a clear slightly gelatinous fluid and at least 20 opaque, white, small cestode scoleces (Figure 1A). The cestode scoleces resembled grains of sand arranged in multiple rows (Figure 1B). The lateral ventricles were slightly dilated. There were no other gross lesions.

HISTOPATHOLOGY FINDINGS:

The brainstem contained a large cystic mass lined by an internal germinative membrane forming a bladder. Attached to the internal germinative membrane were multiple cestode scoleces characterized by a rostellum armed with hooks, suckers, and calcareous corpuscles suspended in a parenchyma covered by a tegument (Figure 2). The neuropil adjacent to the bladder was compressed and contains perivascular cuffs of small numbers of lymphocytes, plasma cells and eosinophils.

LABORATORY FINDINGS:

Rabies testing of the brain was negative.

DIAGNOSIS:

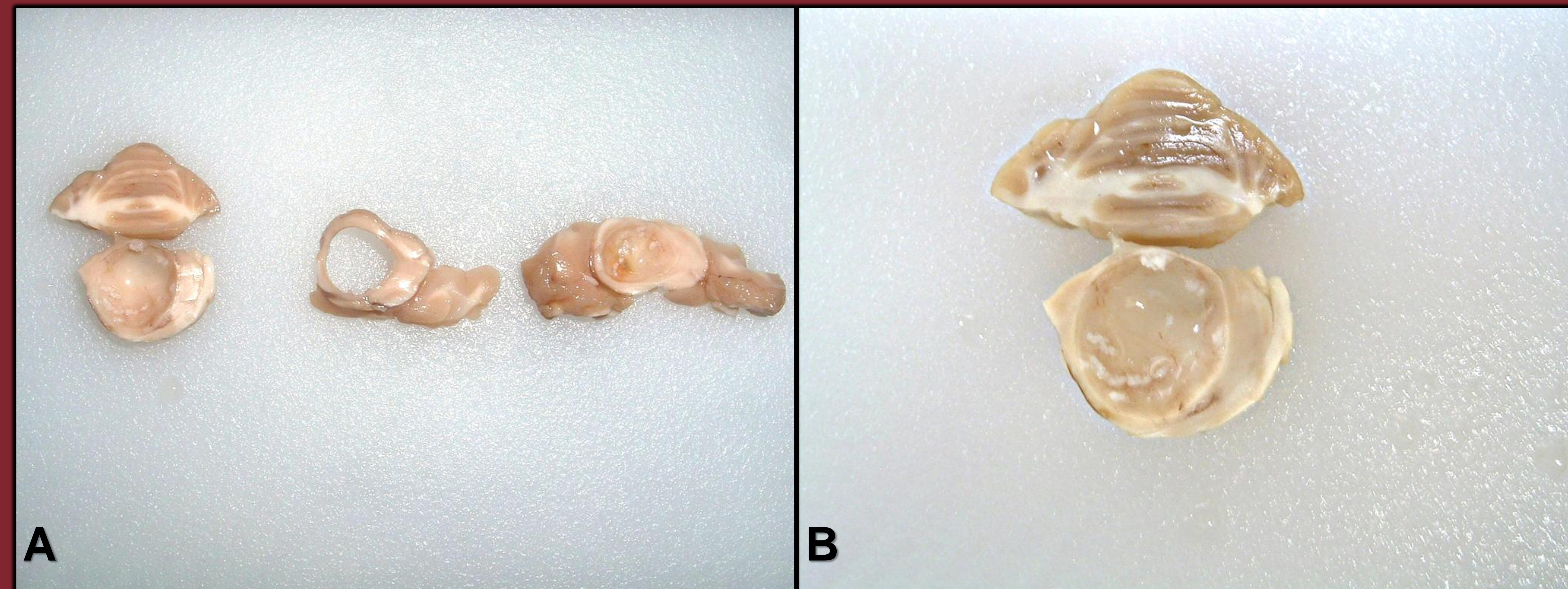
Cerebral coenurosis in a two-year-old Domestic Short Hair cat

The coenurus was most likely caused by *Taenia serialis*.

DISCUSSION:

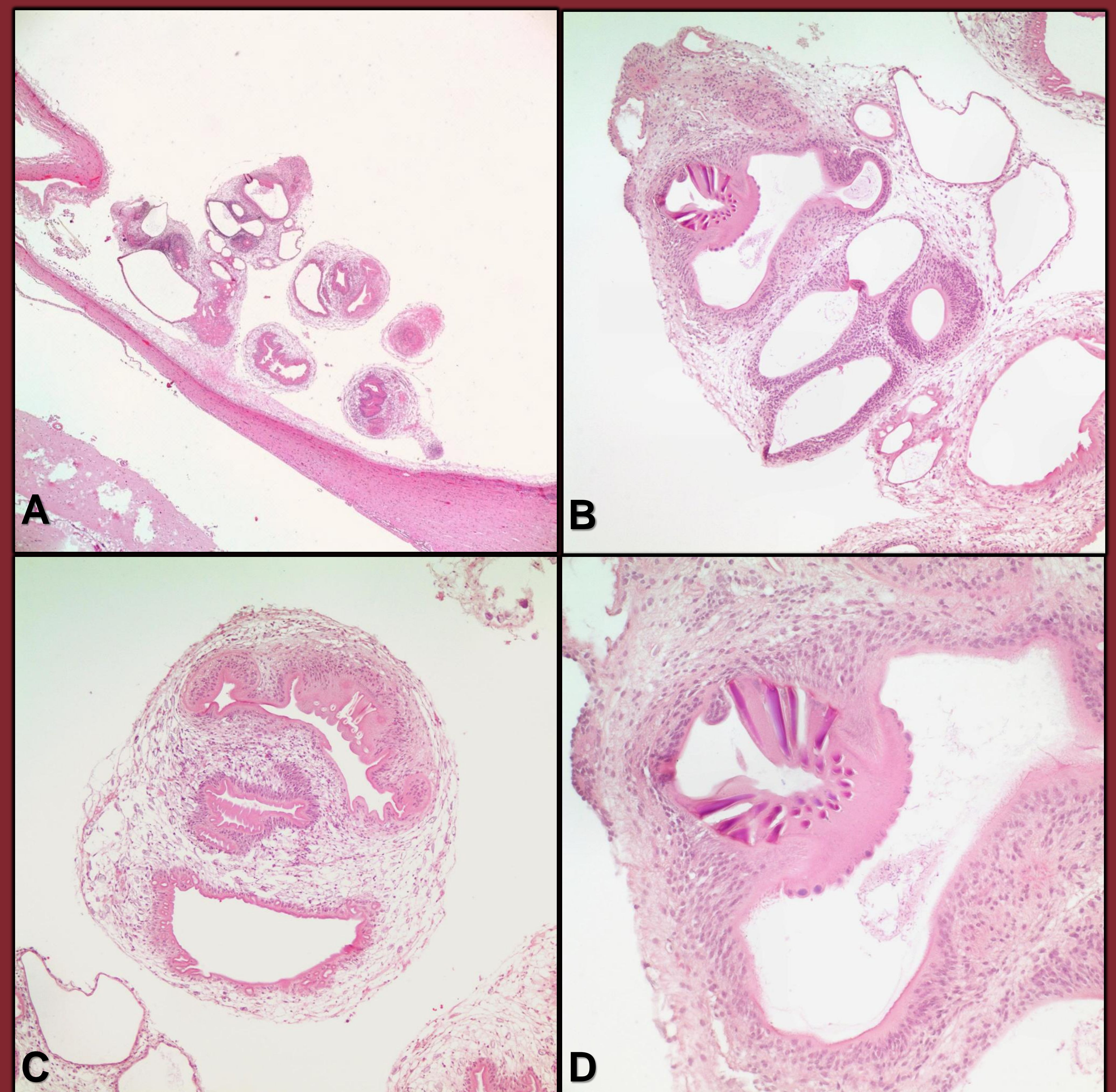
Cerebral coenuri occur rarely in cats. The two species of cestodes that most frequently cause coenuri are *Taenia multiceps* and *Taenia serialis*. The arrangement of the scoleces in a linear arrangement within the coenurus as well as the elimination of *T. multiceps* from the United States, suggest that the cestode causing the coenurus in this case is *T. serialis*. *Taenia serialis* has a canid-rabbit life cycle with rare aberrant infections in cats.

FIGURE 1:



Photographs of the cross sections of the formalin-fixed brainstem of a two-year-old cat with a cerebral coenurus.

FIGURE 2:



Photomicrographs of the cestode scoleces within the coenurus in the brainstem of a two-year-old cat.